

PATIENT

Rissa Olson

SPECIES

Feline

BREED

Sphynx

SEX

Female Spayed

AGE

5.4 years

WEIGHT

13.2lbs

INTERPRETED BY

Maggie Machen Lamy,
DVM, DACVIM
(Cardiology)

IMAGING PERFORMED BY

Greg Kuhlman, DVM

HOSPITAL NAME

Red River Animal
Emergency Hospital &
Referral Center

REFERRING VET

Dr. Kuhlman

INVOICE

46619

DATE

1/29/26

PRESENTING CLINICAL SIGNS

History: Presented on 1/9/26 for coughing starting 1/7/26 and seeming like she has a hard time swallowing after. Eyes appeared weepier than normal, always have been. Discharge is usually clear, sometimes brown. Started on Hydroxyzine 5mg PO BID for epiphora and mild upper airway congestion. Elevated BNP. BP: 130mmHg.

ECHOCARDIOGRAM FINDINGS

2D, m-mode, color flow and doppler imaging is available. The left ventricular wall is normal in dimension. There is a mildly hyperechoic endocardium consistent with mild fibrosis. The endocardium also appears mildly remodeled. The papillary muscles are normal in size and hyperechoic. The left atrium is normal in size. The right atrium is normal in size. The right ventricle appears normal. The mitral valve is normal in structure and mobility. No obvious valve regurgitation. Blood flow through both the LVOT and RVOT is normal in velocity. No pleural or pericardial effusion seen. No obvious cardiac tumors.

CARDIAC CHART

FELINE CARDIAC PARAMETERS	BODY WEIGHT (kg)	HR (BPM)	IVSd (cm) (Moise, Pipers)	LVIDd (cm) (Moise, Pipers)	LVWd (cm) (Moise, Pipers)	FS (%)	EF (%)
NORMAL PARAMETER	-----	150-240	0.35-0.55	<2 (mean 1.5)	3.5-0.55	35-67	80-100
PATIENT	6.0	NM	0.45	1.2	0.45	57	88
FELINE CARDIAC PARAMETERS	LA/AO (Boon)	LA/AO HEART BASE (Swe) (Abbott)	LA 2D short axis Base view (cm) (Abbott)		LVOT VEL (m/s)	RVOT VEL (m/s)	E max (m/s)
NORMAL	<1.5	<1.3	<1.2		<1.6	<1.3	<0.9
PATIENT	NM	1.3	1.3		0.9	0.8	NM
<p><i>*Note: All measurements based upon multi-modal images and methods. An average value is reported.</i> Adapted from June Boon, Veterinary Echocardiography, 1998 Abbott J & MacLean H JVIM 2006;20: 111-119, Moise et al. Am J Vet Res 47:1476, 1986. Pipers et al. Am J Vet Res 40:882, 1979.</p>							

INTERPRETATION OF THE FINDINGS & FURTHER RECOMMENDATIONS

Overtly normal cardiac structure and function. The LV wall thickness is normal, and there is no evidence of elevated left atrial pressure or underlying pathology at this time. There is mild remodeling and fibrosis of the left ventricular wall, which is considered likely a normal age-related finding. No significant valve regurgitation is seen and flow through the great vessels is normal.

Given these findings, no medications are indicated. A reported cough is certainly noncardiogenic in origin and further workup should be dictated by IM.

No obvious structural cause for BNP elevation is seen here. A flaw of the BNP test is false positives, which is suspected in this normotensive young cat. Serial monitoring is advised.

Anesthetic risk is considered mild. Risk for complication with steroid use typically follows LA dilation, which in this case is low. That being said, any cat can experience unexpected signs of intolerance and monitoring of RR/RE is advised particularly in the initiation phase.



PATIENT

Rissa Olson

SPECIES

Feline

BREED

Sphynx

SEX

Female Spayed

AGE

5.4 years

WEIGHT

13.2lbs

INTERPRETED BY

Maggie Machen Lamy,
DVM, DACVIM
(Cardiology)

IMAGING PERFORMED BY

Greg Kuhlman, DVM

HOSPITAL NAME

Red River Animal
Emergency Hospital &
Referral Center

REFERRING VET

Dr. Kuhlman

INVOICE

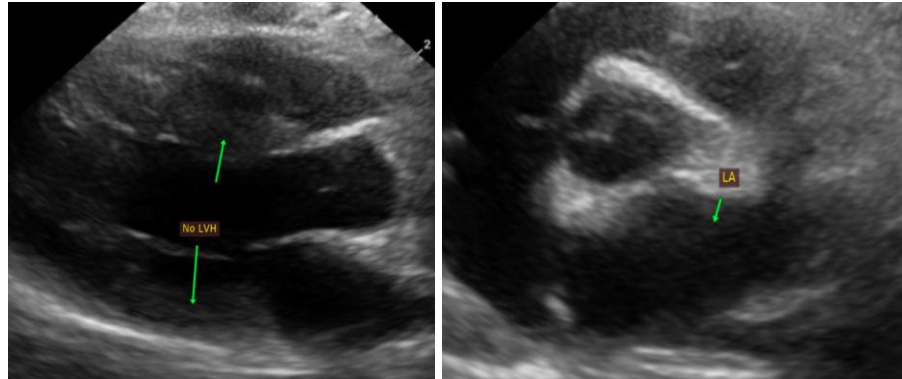
46619

DATE

1/29/26

Recommend recheck echocardiogram in 1 year to assess for any progressive issues.

IMAGES



The information and recommendations provided are based on the images presented by the referring veterinarian. No evaluation can be communicated regarding pathology that was not visible in the image/video clips provided.

Thank you for this referral. This report was generated using transcription software, and minor dictation errors may be present. If the clinical or image interpretation does not parallel your findings or if I can be of any further assistance, please contact me.

Maggie Machen Lamy, DVM

Diplomate of the American College of Veterinary Internal Medicine (Cardiology)

info@sonopath.com